IJNU Review Article

Int J Nephrol Urol, 2009; 1(1): 14 - 26

Chyluria - An Overview

Sachit Sharma, Ashok Kumar Hemal*

Department of Urology, All India Institute of Medical Sciences, New Delhi, India

Abstract

Chyluria, recognized as a urological manifestation of lymphatic system abnormality has been a curious entity since long. With varied options for management, this tropical, debilitating disease is known for recurrence. The article provides an in-depth review into the subject with the author's experience in the field along with the recent advances in management. This article also describes the entity from its historical background, etiopathogenesis, investigative and management protocols including complications. Recent treatment modalities reported in literature are reviewed with author's innovative contributions in the form of applying MR scan for diagnosing and robotics for treating chyluria.

Keywords: Chyluria, Laparoscopy, Recurrence, Sclerotherapy, Surgery

Chyluria, recognized since the time of Hippocrates (400BC) is described as the passage of milky appearing white urine due to the presence of chyle composed of albumin, emulsified fat and fibrin in varying proportions that are absorbed by intestinal lacteals. It is associated with spontaneous remissions and exacerbations. Although rare in the West, it is not uncommon in Asia. It has been recognized as a tropical disease more prevalent in the rural and poverty stricken population. This review article provides an in-depth into the subject with the author's experience in this field along with the recent advances in management (1-4).

History of Hypothesis

The following were the explanations in the past for causation of chyluria:

Prout (1841): Secretion of fat from blood through kidneys (5).

***Ackerman (1863)*:** Blockage of major lymphatics or thoracic duct causing retrograde flow of lymph from the gut and pelvis into lumen of GIT (6).

***Wucherer (1869)*:** Presence of microfilaria in blood/urine of chylurics (7).

***Lazarus and Marks (1946)*:** Presence of fistulous openings in bladder causing chylous efflux from ureteric orifices (8).

***Manson-Bahr (1954)*:** Rupture of lymph varix anywhere in urinary tract leading to escape of lymph in urine (9).

***Sen and Elappan (1968)*:** Parasitic / bacterial infections → fibrosis →reduced lymphatic bed→lymphatic HT→lymph stasis & shunt formation (10).

** Correspondence:*
Ashok Kumar Hemal, M.D
Department of Urology, All India Institute of Medical Sciences,
Ansari Nagar, New Delhi, India -110029.
Tel: +91-9868397431
Fax: +91-11-26588641
Email: ahemal@wfubmc.edu
Received: 27 Mar 2009
Accepted: 20 Apr 2009

Recently the following theories have been implicated as causative factors:

Obstructive theory (Aye and Aung, 1975): Inflammatory reactions due to parasitic infestation lead to obliterative lymphangitis, lymphatic HT, valvular incompetence and retrograde flow of chyle producing a lymphatico-renal shunt (11).

***Regurgitative theory (Ngan and Leong, 1977)*:** Toxic metabolites or immune reaction to parasitic infestation leads to lymphatic ectasia and varicosities, that rupture, releasing chyle from dilated intestinal lymphatics into the renal system (12).

Etiopathogenesis

Chyluria is associated with abnormal retrograde or lateral flow of lymph from the intestinal lymphatics of the kidney, ureter or bladder allowing chylous material to be discharged into the urinary collecting system (1). Various causative factors have been implicated. Passage of chyle into the urine has been related to a consequence of the rupturing of the lymphatic varices leading to the aperture of one or more perirenal lymphatic vessels to the pyelocaliceal system, characterized by milky urine, rich in protein, lipids, cholesterol and triglycerides. A malformation of the chyliferous vessels of the small intestine associated to hypoplasia of Pecquet's cistern has also been suggested.

On anatomical basis, the renal lymphatics follow the renal vein and end in lateral aortic glands; efferents from which flow to the lumbar trunks. The intestinal trunks receive lymph from stomach, intestine, pancreas, spleen and liver. Physiologically chyle travels from the lacteals to the cisterna chyli or thoracic duct. Pathological obstruction and/or insufficiency of the valvular system of lymph channels leads to retrograde flow to lumbar lymph glands draining renal lymphatics. Thus there is a short circuiting of chyle drainage from intestinal lacteals to renal lymphatics.

Classification

The classification is based on the etiological factors- broadly divided into two groups, parasitic and non parasitic (Table 1). Although rarely seen in some countries, however its prevalence is high in areas where infections with Wuchereria bancrofti are endemic. Chyluria is extremely rare in Europe, but is frequently reported from Asian countries like India, China, Taiwan and Japan (13-17). Epidemiological surveillance since 1984 indicates that the transmission of infection has been interrupted (18). Approximately 120 million people worldwide are affected by lymphatic filariasis.

Chyluria can also have non-parasitic causes of which only a few cases have been described. Chyluria due to a congenital fistulous communication between the lymphatic system and the bladder has been described in children (19). Chyluria may occur as an exceptional complication of retroperitoneal lesions in lymphangiomatosis in rare cases (20, 21).

Chylous ascites and chyluria have been reported in nephrotic syndrome with focal segmental glomerulosclerosis and nephrotic syndrome due to retroperitoneal lymphangioma. Hypoalbuminemia-induced bowel edema may predispose to change in the permeability of mucosal or serosal lymphatics resulting in chylous ascites (22, 23).

Clinical features

The most common clinical symptom is passage of milky urine in up to 70% cases (24). Other symptoms include chylous clot, bloody and milky urine, dysuria, frequency, urgency and urinary retention in decreasing order of presentation. Constitutional symptoms include weight loss, low-back ache, fever, chills and hydrocele. The duration of symptoms may be as long as 2- 11 years (1). The disease is significantly higher in males (86%) than in females (14%) (25). It has been more frequently reported on the left side (26). Majority of the cases present in the second and

Table1. Classification of chyluria based on etiological factors

Parasitic (primary-tropical)	Non-parasitic (secondary-nontropical)
● Wuchereria bancrofti (90%) ● Taenia echinococcus ● Taenia nana ● Ankylostomiasis ● Trichiniasis ● Malarial parasites	● Congenital ● Lymphangioma of urinary tract ● Megalymphatics & urethral/vesical fistulae ● Stenosis of thoracic duct ● Retroperitoneal lymphangiecatasia ● Traumatic lymphangiourinary fistulae ● Obstruction of thoracic duct/ lymphatics (tumor, granulomas, aortic aneurysm) ● Other causes (pregnancy, diabetes, abscess) ● Nephrotic syndrome

third decade of life. About 70% cases have genital manifestations, 25% lymphatic obstruction in limbs and 5% suffer from manifestations like cellulitis, abscesses, hematuria and chyluria. Previous history of filariasis or its complication has been documented in 19% cases (27).

Grading

The severity of the disease can be graded into (1):

Mild chyluria (34-50%): Intermittent milky urine; no clot colic/chylous coagulum/urinary retention/ weight loss; involvement of single calyx on RGP.

Moderate chyluria (33- 40%): Intermittent continuous milky urine with occasional clot colic/ chylous coagulum; no urinary retention/weight loss; involvement of 2 or more calices on RGP.

Severe chyluria (15- 26%): Continuous milky urine with clot colic/chylous coagulum/urinary retention /weight loss; involvement of most of calices with/without involvement of ureter on RGP (1).

Investigations

Urinary Examination

A fatty diet a day or night before enhances chyluria and helps in its diagnosis. A fresh sample of urine is grossly inspected. The classical urine in chyluria is like milk, frequently containing a semisolid gel, blood and fibrin clots. On standing in test tubes, it separates into a top fat layer, middle fibrin and bottom layer of cells and debris. Microscopic examination of the sediment comprises of erythrocytes and lymphocytes. In the presence of symptoms like milky urine, proteinuria and leukocyturia in the urinary sediment and a negative urine leukocyte stick test and absence of infectious signs, chyluria must be suspected (13).

Ether test

Vigorous shaking (few minutes) with equal amount of ether clears opacity.

Methylene blue test

Fresh stain with one/two drops of 1:1500 reveals small lymphocytes (single/clump).

Sudan III test

Oral ingestion of fat labelled with Sudan III (10 gm butter + 100 mg Sudan red III) causes orange pink colouration of urine in chylurics within 2-6 hours.

Biochemistry

Urinary triglycerides are invariably present in morning sample, 100% sensitive/specific test. Postprandial urine lipids, especially triglycerides (TGs) ranging from 10 to 1955 mg/dl, might be used as markers for the clinical evaluation of chyluria. Urine albumin is abnormally high in most cases (16).

Immunoelectrophoresis

Shows globulins of various types of apolipoprotein A 48 (of intestinal origin).

Cystourethroscopy

Helps to localize the side of milky efflux from one/ both ureteric orifices. Rarely chylous efflux may be seen from bladder or even posterior urethra. A fatty diet previous day/night enhances results. Ureteric catheterisation (5-6 F) and split urinanalysis may be

done simultaneously.

Retrograde pyelography (RGP)

With help of fluoroscopy and spot films it demonstrates pyelolymphatic backflow. RGP is not specific as the same is also seen in normal kidneys if contrast is injected under pressure. 20° Trendelenberg position is used under fluoroscopy for ureteric catheterization to reach renal pelvis after cystoscopically identifying laterality of efflux. Gravity propagated contrast instillation prevents sudden distension of renal pelvis which may lead to loin pain due to opening up of pyelovenous/pyelosinus channels thus causing inadvertent reactions.

Lymphangiography

Lymphangiography is the preoperative imaging procedure of choice and the most powerful diagnostic tool as it demonstrates the site, the caliber and the number of the fistulous communications. It can also diagnose vascular dysplasias of the lymphatic vessels (28). Findings generally include lymphatico-urinary fistulae at level of kidney, ureter or bladder; tortuous dilated lymphatics around hilar region (lymphangiectasia) communicating with paravertebral lymphatics; contrast outlining major/minor calyces. Other findings that may be seen include tortuosity and beading of thoracic duct, round granular enlarged nodes in paraortic area, skipping of lymphatic chain, dilated cisterna chylii and abnormal lymphatics coursing down along the ureters. In 40% cases contrast may enter PCS and drain via bladder.

It is not routinely done as it is time consuming, technically demanding and invasive (29).

Unilateral pedal lymphangiography can detect lymphaticorenal fistulae via lymphatic crossover even when it is on the side opposite from which contrast agent has been injected. The advantages of unilateral lymphangiography over bilateral procedures are that it is easy to identify crossover channels, and the discomfort for the patient is reduced because there are fewer incisions and it is quicker (29, 30).

Lymphangioscintigraphy

Though useful in delineating the site of the fistula it is not as precise as lymphangiography. However, it is a useful, noninvasive, safe, simple technique using Tc99 human serum albumin sulphur colloid, Tc-99m diethylenetriamine pentaacetic acid, 99mTc-antimony sulfide colloid or dextran. It is the investigation of choice (if available) to localize, lateralize and to know the functional extent of reflux and to detect recurrence on follow-up. It can demonstrate abnormal lymphatic drainage in chylurics and allows functional assessment of lymphatic transport and depiction of regional lymph nodes. A rapid and non-traumatic investigative procedure, it has no known side effects (31-33).

Immunological Studies

ELISA Test: The test is useful in diagnosing cases where causative agent is suspected to be filarial and is based on humoral immune response of host to filarial antigen. Filarial IgG antibodies against microfilarial excretory-secretory (mf ES) antigen have been detected in 89% of cases with genital manifestations, 87% with lymphoedema, 67% with lymphadenitis and 60% with other clinical manifestations. With a 85% specificity and 95% sensitivity, it is positive in 3% of endemic normals (25).

Immune function of the patients who present with filarial chyluria is impaired in terms of the changes in T-lymphocyte subsets. The percentage of CD3+, CD4+ cell is significantly decreased, the ratio of CD4+/CD8+ being under 1.0 (34). Both cell-mediated and humoral immunity are low in chyluric cases. OKT3 and OKT4 levels are commonly low, and OKT8 is higher than normal value with the OKT4/OKT8 ratio inverted (35).

Ultrasonography : Echolucent areas may be seen within blood clot due to the chylous component; leading to heterogenous character of clot. This needs to be differentiated from carcinoma bladder.

Intravenous pyelography : Rarely used to demonstrate dilated para-calyceal lymphatics (need for application of ureteric pressure), it may delineate increased renal size in severe disease state due to obstruction. Overall it is not a cost effective

investigation.

CT scan : Fat in the bladder secondary to chyluria can be picked up on CT (36). Dilated lymphatic channels may mimic a mass of confluent low-density lymph nodes (37).

MR scan (Figure 1) : A non-invasive and less time consuming study -best to delineate anatomy (but no functional assessment). It is most useful in cases where site of obstruction is lower ureter/bladder. On MR urography, the lymphatic channels are seen as a meshwork of multiple tubular, tortuous, fluid filled structures in the retroperitoneum of the abdomen and pelvis. On axial T1W images, these channels are seen as numerous, interconnected small, nodular and streaky intensities and as a cloak of diffuse homogenous hyperintensity on T2W axial images (37). An innovation of the author, the results of this useful modality of investigation are being evaluated.

Renal biopsy : Mainly undertaken for academic research generally shows immune complex type of glomerulonephritis (38).

Others : Serum type I collagen and type III procollagen are decreased in patients with filariasis. In contrast, serum hyaluronan (linked to perilymphatic granulomatous inflammation) and serum eosinophil cationic protein is significantly increased in patients of fileria exhibiting chyluria (39).

Management

Non surgical management

Dietary modifications: As absorption of dietary fats leads to chyle formation, hence a fat restricted diet is recommended (<25 g/day). Fats containing MCT (<12 C atoms) are absorbed directly through portals- hence use of coconut oil recommended (40). In heavy chyluria, parenteral administration containing fat as MCT with albumin is given. TPN with enteric rest is advised in intractable chyluria (41).

Diethyl carbamazine (DEC/ Hetrazan / Benocide): The dose is 6mg/kg in 3 divided doses after food for 10-14 days (42). Ivermectin 400mg/ kg (single dose) and/or albendazole 400mg may be given along with DEC as symptomatic treatment where filarial infection seems to be the cause.

Supportive treatment: High protein diet is advised to make up for the albumin lost in the form of chyle. Hematinics, multivitamins and green leafy vegetables are recommended in hematochyluria. Bed rest, anti-inflammatory, analgesics and antipyretics are useful in managing in associated lymphadenitis. Abdominal binders may be applied during acute attacks of chyluria to reduce loss of chyle. Cytoscopic bladder wash is recommended in cases of clot/chylous urine retention and/or recurrent urinary tract infections.

Sclerotherapy (Table 2): Comprises of instillation of renal pelvis with chemicals - silver nitrate (0.1-3.0%), 0.2% povidone iodine, 15-25% sodium iodide, 10-25% potassium iodide, 50% dextrose, 76% hypertonic saline, combination therapy using 5/6 F ureteric catheter after localizing site on cystoscopy in cases of failure of conservative management i.e. dietary modifications and as prophylaxis. These agents bring about relief by causing chemical lymphangitis (Diagram 1).

Permanent relief: The procedure is performed under LA/ sedation with aseptic precaution keeping the head down (20^0) and instilling 7-10ml sclerosant

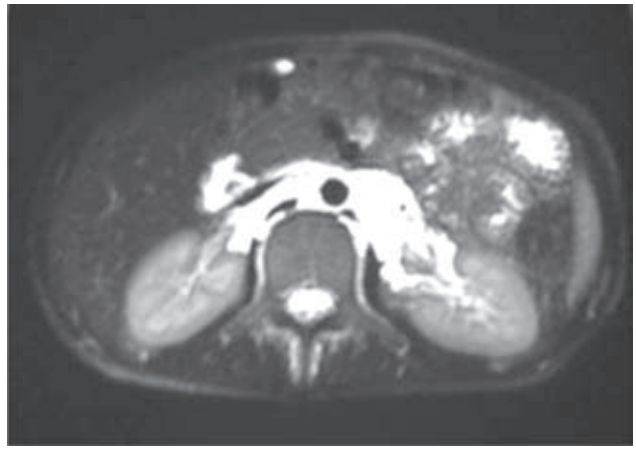

Figure 1. Non-invasive MR scan shown extensive involvement of bilateral lymphatics with good anatomical background

under gravity (fluoroscopy assisted). Analgesic / antibiotic cover is given for at least 5 days. Dosage schedule is 8 hourly for 3 days or 12 hourly for 2 days or weekly for 6-8 weeks. Recurrence after 1st course can be treated for second time with high success rate. Patients with shorter as disease free duration fare poorly with second course. In bilateral efflux gap period of minimum 6-8 weeks between 2 sittings is recommended (43).

Silver Nitrate (0.1-3.0%): It is most commonly used sclerosant till date. 2gm silver nitrate powder is dissolved in 200ml of water in a bottle (black paper/dark room). The need for sterilization (autoclaving) results in a 8-24 hr undesirable delay. Other disadvantages include procuring and precisely weighing good quality silver nitrate, water insolubility, susceptibility to light, and precipitation with normal saline to form insoluble silver chloride salts that may cause uretric obstruction. As even mortality has been reported due to acute tubular necrosis (ATN) on instillation of silver nitrate in both ureters simultaneously, care needs to be observed (44, 45).

Povidone Iodine (0.2%): It is a water soluble, non-ionic surfactant polymer that releases iodine slowly. Prepared by mixing 2ml 5% povidone iodine to 8ml distilled water it is to be used as a fresh solution. It is as effective as 1% silver nitrate with no side effects like flank pain, nausea, vomiting, interstitial nephritis, chemical cystitis, papillary necrosis and ATN. Also having antiseptic antibacterial and antifungal properties (46) it is considered safe and effective for managing chyluria (15).

Combination therapy: Combination sclerotherapy using a 5% povidone iodine and 50% dextrose solution has been found to be a safe and cost-effective minimally invasive therapy for chyluria refractory to conservative treatment. 5ml of 50% dextrose combined with 5ml 0.2% povidone iodine provides stronger and better fibrotic response (24).

Heat-clearing and hemostatic treatment: 26 out of 30 patients of chyluria have been reported to be cured completely with a basic heat-clearing and hemostatic prescription (35).

Surgical management: Surgery is the treatment of choice in severe forms of chyluria i.e. significant weight loss; hypoproteinemia, anasarca, and/or severe anemia; recurrent clot retention and hematochyluria; recurrent UTI; refractory chyluria (failure of conservative treatment with adequate dietary modification, medical management and two or more instillations of sclerosants); clinically significant chyluria (associated with chylous clot or

Table 2. Results of sclerotherapy of different series

Study	Year	Response (%)	FU (months)	Recurrence (%)
Silver Nitrate				
Yu et al (70)	1978	119/161 (74%)	-	26%
Ohyama et al (71)	1979	- (62%)	2 –115	37%
Okamoto and Ohi (72)	1983	129/217 (59%)	24	40%
Tan et al (73)	1990	46/55 (83%)	24	16%
Sabnis et al (74)	1992	51/62 (82%)	24 – 84	18%
Povidone Iodine				
Shanmugam et al (75)	1998	5/5 (100%)	6	-
Goel et al (46)	2004	36/41 (88%)	24	12%
50% Dextrose				
Goel et al (46)	2004	20/21 (95%)	5.2	98%
Povidone Iodine + 50% dextrose Nandy et al (24)	2004	40/46 (87%)	24	13%

hematochyluria or duration of more than 1 year or failure to respond to conservative medical measures) (47); altered immune status; marked psychological disturbance.

Open surgical techniques

Lympho-venous disconnection: First described by Katamine in 1952 it is the most commonly performed procedure. A fatty diet 24-36 hr prior to surgery facilitates detection of lymphatics. Pedal lymphangiography and/or methylene blue injection delineates the lymph channels. Reno-lymphatic disconnection operation is performed via a lumbar incision. The kidney is freed, lymphatics in hilar area coursing along the renal vein are dissected, ligated & cut. Areolar tissue containing dilated lymphatics travelling to the kidney in the perirenal and hilar region are dissected and divided between ligatures - thus stripping these structures completely. Hilar stripping is continued up to proximal 3-4cm ureter, the site for majority of shunts. Recurrence or bladder leak on imaging, mandates stripping of the entire ureter (48).

Patna operation (1977): It is a modified procedure of peri-ureteric lymphovenous stripping. Disconnection of only abdominal ureter is done without hilar disconnection. "Ureter in Lymphatic Tunnel" i.e. pampniform plexus in front and pre/para aortic plexus behind is the basic concept followed (49).

Omental wrapping (2004): Omentum is used to wrap the renal vessels after stripping both anteriorly and posteriorly. This reduces the incidence of postoperative lymphatic drainage, lymphocele formation, recurrence, fibrosis and postoperative adhesions (47).

Renal autotransplantation: This is rarely indicated for fistulas in the lower portion of ureter /bladder or when renal pedicle stripping has failed (incomplete procedure/ recanalization) or there is formation of newer fistulas (50).

Nephrectomy: It is used only for kidneys rendered non-functional following lymphovenous disconnection and serves as a life saving measure in severely refractory chyluria (51).

Diagram 1. Sclerotherapy – Mechanism of Action

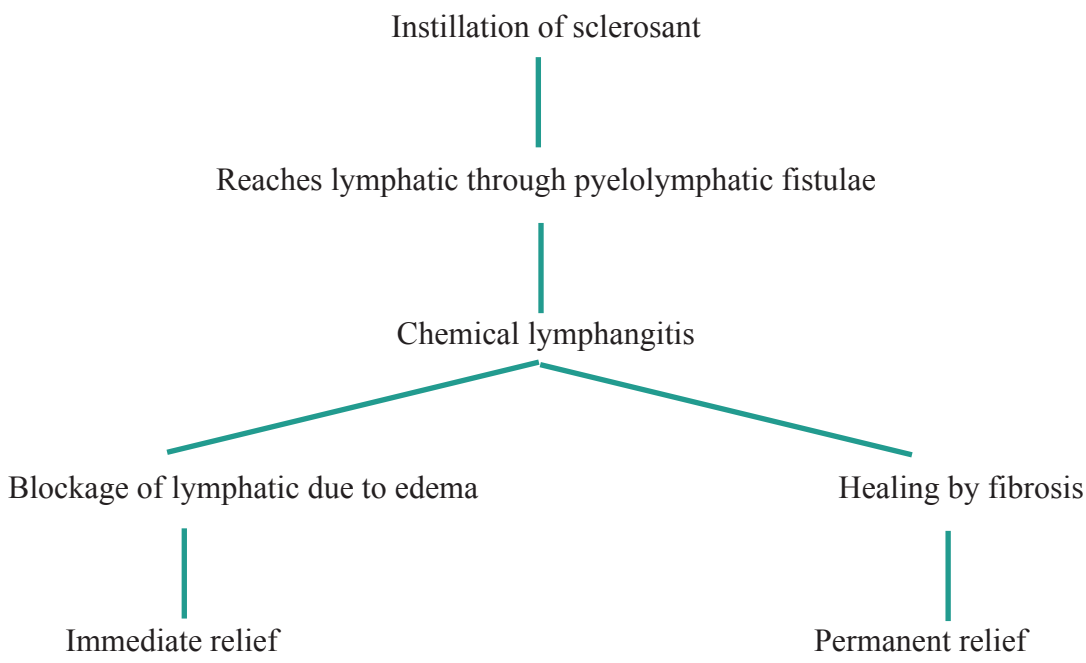

Cockett and Goodwin procedure (1962): The procedure is based on diversion of a single hilar lymphatic to a spermatic/gonadal vein in end-to-side fashion. It provides a safety valve mechanism for renal lymphatic hypertension-the basis of chyluria. It obviates need for complete stripping and there is a decreased incidence of lymphocutaneous fistula. However, the demerits include increased operative time, technical difficulty and need for magnification (52).

Microsurgical procedures: Recommended in the old and debilitated patients unable to tolerate ligation / division of lymphatics this technique has been found useful in persistent or recurrent chyluria. Aiming to physiologically decrease the intra lymphatic pressure by increasing lymph drainage into venous system it reduces incidence of lymphangiectasia and facilitates healing of lymphatic fistula in the renal papilla. A simple, easy relatively superficial procedure – less traumatic to surrounding tissues it obviates the use of CPE / lymphangiography as there is no correlation between site of operation or side of lympho-renal fistula. Technically demanding - magnification is very essential as 90% of lymphatic vessels have diameter <1mm making it difficult to finding vein of adequate diameter and in proper place (for anastomosis).

Lymphangiovenous anastomosis: An end-to-end anastomosis is made in the inguinal region in men (Figure 2) and either in dorsum of foot/leg/thigh in women. 3 to 4 anastomoses per side are made using 4 to 6 interrupted (9-11) 0 nylon sutures (53).

Lymph node – Saphenous vein anastomosis: An end-to-side anastomosis of inguinal lymph node to generally a tributary of saphenous vein (the distal end of which is ligated) is made. Generally a single anastomosis using 6 to 7 interrupted sutures is sufficient (54).

Laparoscopic procedures: The objectives of open surgical treatment of intractable chyluria can be achieved by the minimally invasive laparoscopic techniques with the added advantages of magnified view, better identification of lymphatics, better anastomatic results, minimal morbidity, shorter hospital stay, excellent cosmesis and early return to work. Of the two main routes i.e. transperitoneal (peritoneum transgressed) and retroperitoneal (easy and straight access to kidney) the latter approach significantly reduces incision – related morbidity without compromising the principles of open surgery (2).

Retroperitoneoscopy: The technique of retroperitoneoscopic management of chyluria comprise of nephrolympholysis, ureterolympholysis, hilar vessel stripping, fasciectomy or nephropexy out of which the first three are mandatory while fasciectomy and nephropexy (to prevent renal pedicle torsion and nephroptosis) are not routinely recommended (1).

Retroperitoneoscopic renal pedicle lymphatic disconnection for chyluria completely ligates the lymphatic vessels and is a safe, effective and efficient surgical procedure with minimal invasion, less pain, less blood loss, lower morbidity, short hospital stay and rapid recovery (55, 56). The procedure is recommended for treatment of recalcitrant chyluria (57).

Robotics: The author has been a pioneer in the use of this modality of management for chyluria. Nephrolympholysis, ureterolympholysis, hilar vessel stripping, fasciectomy and nephropexy can all be done as in conventional laparoscopy. This state-of-the-art Master-Slave system provides 3-dimensional vision, seven degress of freedom, 540 wristed movements, elimination of hand tremors, accurate scaling of movements and ergonomic comfort in addition to the advantages and objectives of open surgery (58).

Other therapies

Medical therapy: Posttraumatic chyluria due to lymphorenal fistula has been found to regress after somatostatin therapy (59). Chyluria has been reported to disappear following percutaneous sclerotherapy to the left inguinal lymph nodes with doxycycline in a postoperative case of lymphangiomatosis (60). Chyluria (after radical nephrectomy) has o been treated with N-butyl-2-cyanoacrylate (61).

Gerota's fasciectomy: Bilateral excision of the

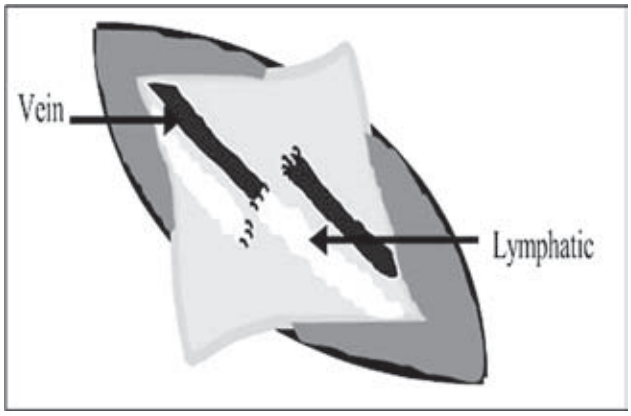

Figure 2. End-to-end lymphatico-venous anastomosis using spermatic cord (males)

perinephric fascia and fat (Gerota's fasciectomy) in 2 stages has been reported to result in complete resolution of chyluria (62).

Endoscopic therapy: Chyluria has been successfully treated in 5 patients with endoscopic coagulation using guide tube methods (63).

Recurrence

Incomplete stripping, recanalization, reflux from contralateral side, reflux from terminal ureter or bladder are important causes of recurrence generally diagnosed by radio imaging especially lymphangioscintigraphy, lymphangiography (detects leaks at bladder level) and cystoscopy (blebs under mucosa / loosely hanging chylous clots from bladder wall). This can however be prevented by use of magnifying loops, operating microscope, omental wrap technique or the use of laparoscope.

Complications

Although, Sclerotherapy is described as a relatively safe procedure, few complications have been reported with it. These include anuria with pelvi-calyceal cast formation, acute necrotizing ureteritis and fatal renal and hepatic failure (64-67). Complications of retroperitoneoscopic surgery are few - inferior vena cava injury, renal segmental artery injury, lymphatic leak through the drain, and delayed wound healing. Advancements in laparoscopy with the advent of robotics is a step forward to minimize the complication rate (58).

Conclusions

Acute manifestations of filaria and chyluria have been reported to disappear or greatly improve after filariasis eradication by a low dose of DEC medicated salt for a period of 6 months while chronic ones remained unchanged (68).

Table 3. Follow up results of operative procedures for chyluria in various series

Study	Year	Technique	Complete cure	Improved	No change
Okamoto et al (72)	1983	LVD	375 (97.7%)	5 (1.3%)	3 (0.8%)
Punekar et al (76)	1997	LVD	69 (88.0%)	-	9 (12.0%)
Prasad et al (49)	1977	P	14 (93.3%)	1 (6.7%)	Nil
Dalela et al (47)	2004	LVD +0	4 (100.0%)	Nil	Nil
Brunkwall et al (50)	1990	RA	1 (100.0%)	Nil	Nil
Cockett et al (52)	1962	HLVD	1 (100.0%)	Nil	Nil
Xu YM et al (54)	1991	LVA	30 (60.0%)	6 (12.0%)	14 (28.0%)
Xu YM et al (54)	1991	LNSVA	6 (50.0%)	2 (16.7%)	4 (33.3%)

LVD,lymphovenous disconnection; P, Patna operation; O, Omental wrap; RA, Renal autotransplant; HLVD, Hilar LV disconnection; LVA, Lymphangiovenous anastomosis; LNSVA, Lymphnode saphenous vein anastomosis

The prognosis of non-parasitic chyluria is usually very good and the treatment is mostly conservative (19). A long-term remission rate of 62% in the conservatively managed group (DEC + fat restricted diet), and a cure rate of 90% of patients in the operated group has been reported. Postoperative recurrence rate was 10%. There was more weight gain and dietary freedom along with a longer chyluria free period in the operated group relative to the conservatively managed group (27).

Though pure dextrose treatment has been discontinued due to poor success, povidone iodine 0.2% has been found to be as effective as 1% silver nitrate [82% (silver nitrate) and 83% (povidone; P=1.0)] (45). Definitive surgical ablation of lymphatic urinary fistula is better than conservative medical management because it has a higher success rate, more dietary freedom and better patient acceptability (27). Over 95% success rate has been described with a follow up of 1 to 9 years following a single microsurgical operation (54).

Reno-lymphatic disconnection is the reference procedure, with long-term success rates of 99% (69). The follow up results of various series are depicted (Table 3).

References

1. Hemal AK, Gupta NP. Retroperitoneoscopic lymphatic management of intractable chyluria. J Urol. 2002 Jun;167(6):2473-6.
2. Hemal AK, Kumar M, Wadhwa SN. Retroperitoneoscopic nephrolympholysis and ureterolysis for management of intractable filarial chyluria. J Endourol. 1999 Sep;13(7):507-11.
3. Hemal AK, RS KMP, Gupta NP. The laparoscopic management of chyluria by retroperitoneal access. BJU Int. 2000;86(3):402.
4. Kumar M, Kumar R, Hemal AK, Gupta NP. Complications of retroperitoneoscopic surgery at one centre. BJU Int. 2001 May;87(7):607-12.
5. Prout W. On the nature and treatment of stomach and urinary diseases. third ed: Churchill, London 120; 1841.
6. Maget A. Renal chyluria. Br J Urol. 1967;39:555.
7. Choi JK, Wiedemer HS. Chyluria: Lymphangiographic study and review of literature. J Urol. 1964 Dec;92:723-7.
8. Lazarus JA, Marks MS. Non-parasitic chyluria with special reference to traumatic chyluria. J Urol. 1946;56:246.
9. MansonBahr PH. Tropical diseases sixteen ed. London Balliere Tindall and Cassel; 1954.
10. Sen SB, Ellappan S. Chylous manifestations of filariasis: a clinical and lymphographic study: Part I: Filarial chyluria. Ind J Med Res. 1968;56(10):1535 - 45.
11. Aye UT, Aung STT. Chyluria. Clin Rad. 1975;26:237.
12. Ngan H, Leong CH. A lymphographic study of chyluria. Br J Radiol. 1977 Dec;50(600):863-70.
13. Gluck Z, Ruegger S, Sulser T. A rare cause of nephrotic syndrome in a young woman with flank pain, milky urine and leukocyturia. Ther Umsch. 2002 Mar;59(3):144-7.
14. Gupta NP. Retroperitoneoscopic management of intractable chyluria. Indian Journal of Urology 2005;21(1):63-5.
15. Lin TP, Hsu YS, Chen KK, Lin AT, Chang YH, Wu HH, et al. Chyluria--experience of Taipei Veterans General Hospital. J Chin Med Assoc. 2003 Feb;66(2):109-12.
16. Peng HW, Chou CF, Shiao MS, Lin E, Zheng HJ, Chen CC, et al. Urine lipids in patients with a history of filariasis. Urol Res. 1997;25(3):217-21.
17. Muguruma K, Matsuda T, Koyama Y, Komatz Y. Chyluria treated with inguinal lymphangiovenous and lymph node-venous anastomosis: a case report. Nippon Hinyokika Gakkai Zasshi. 1994 Oct;85(10):1571-4.
18. Cao W, Van der Ploeg CP, Ren Z, Habbema JD. Success against lymphatic filariasis. World Health Forum. 1997;18(1):17-20.
19. Stalens JP, Falk M, Howmann-Giles R, Roy

LP. «Milky» urine--a child with chyluria. Eur J Pediatr. 1992 Jan;151(1):61-2.

20. Guillonneau B, Bouchot O, Buzelin F, Dupas B, Barrier JH, Buzelin JM. Lymphangiomyomatosis: an exceptional cause of chyluria. Report of a case. Prog Urol. 1993 Jun;3(3):484-9.
21. Kekre NS, Arun N, Date A. Retroperitoneal cystic lymphangioma causing intractable chyluria. Br J Urol. 1998 Feb;81(2):327-8.
22. Lewsuwan S, Kanjanabuch T, Avihingsanon Y, Praditpornsilpa K, Eiam-Ong S. A rare case of chylous ascites and chyluria in an adult nephrotic syndrome with focal segmental glomerulosclerosis. J Med Assoc Thai. 2006 Aug;89 Suppl 2:S253-6.
23. Kano K, Arisaka O. Chyluria due to retroperitoneal lymphangioma producing nephrotic syndrome. J Pediatr. 2003 Nov;143(5):685.
24. Nandy PR, Dwivedi US, Vyas N, Prasad M, Dutta B, Singh PB. Povidone iodine and dextrose solution combination sclerotherapy in chyluria. Urology. 2004 Dec;64(6):1107-9; discussion 10.
25. Mehta VK, Lohar H, Banerjee GK, Reddy MV, Harinath BC. Surgical filariasis: immunoscreening for filarial IgG antibodies using Wuchereria bancrofti microfilarial excretory-secretory antigen. J Commun Dis. 1999 Mar;31(1):35-40.
26. Zhang X, Ye ZQ, Chen Z, Chen ZQ, Zhu QG, Xin M, et al. Comparison of open surgery versus retroperitoneoscopic approach to chyluria. J Urol. 2003 Mar;169(3):991-3.
27. Tandon V, Singh H, Dwivedi US, Mahmood M, Singh PB. Filarial chyluria: long-term experience of a university hospital in India. Int J Urol. 2004 Apr;11(4):193-8; discussion 9.
28. Grunert JH, Hendrickx P, Wagner HH. The diagnosis of lymphatic vascular dysplasia and lymphatic fistula formation. Rofo. 1992 Mar;156(3):282-5.
29. Koga S, Nagata Y, Arakaki Y, Matsuoka M, Ohyama C. Unilateral pedal lymphography in patients with filarial chyluria. BJU Int. 2000 Feb;85(3):222-3.
30. Koga S, Nagata Y, Arakaki Y, Matsuoka M, Ohyama C. Lymphangiography of filarial chyluria: injections via right and left feet at different times. Br J Urol. 1992 Mar;69(3):318.
31. Pui MH, Yueh TC. Lymphoscintigraphy in chyluria, chyloperitoneum and chylothorax. J Nucl Med. 1998 Jul;39(7):1292-6.
32. Thet Thet L, Takeda T, Kuramochi M, Sato M, Wu J, Myo M, et al. Tc-99m diethylenetriamine pentaacetic acid (DTPA)-human serum albumin (HSA) radionuclide lymphography for detecting the location of chyluria. Ann Nucl Med. 1998 Aug;12(4):205-7.
33. Nishiyama Y, Yamamoto Y, Mori Y, Satoh K, Takashima H, Ohkawa M, et al. Usefulness of Technetium-99m human serum albumin lymphoscintigraphy in chyluria. Clin Nucl Med. 1998 Jul;23(7):429-31.
34. Gu XT, Gao ZG, Shen BR, Hu GZ, Tang XL, Ma Q. [Changes in T-lymphocyte subsets of peripheral blood in patients with filarial chyluria]. Zhongguo Ji Sheng Chong Xue Yu Ji Sheng Chong Bing Za Zhi. 2000;18(2):103-5.
35. Xing C, Xing XM, Xing L. Immunological observation on chyluric patients with heat-clearing and hemostatic drugs. Zhongguo Zhong Xi Yi Jie He Za Zhi. 1994 Oct;14(10):601-3.
36. Miller FH, Keppke AL, Yaghmai V, Gabriel H, Hoff F, Chowdhry A, et al. CT diagnosis of chyluria after partial nephrectomy. AJR Am J Roentgenol. 2007 Jan;188(1):W25-8.
37. Govil S, Justus A, Lakshminarayanan R, Nayak S, Devasia A, Gopalakrishnan G. Retroperitoneal lymphatics on CT and MR. Abdom Imaging. 2007 Jan-Feb;32(1):53-5.
38. Date A, Shastry JC, Johny KV. Ultrastructural glomerular changes in filarial chyluria. J Trop Med Hyg. 1979 Jul;82(7):150-4.
39. Esterre P, Plichart C, Huin-Blondey MO, Nguyen LN, Hartmann D, Guerret S, et al. Circulating fibrosis markers, eosinophil cationic protein and eosinophil protein X in patients with Wuchereria bancrofti infection: association with clinical status. Parasite. 2006 Jun;13(2):165-70.
40. Geliebter A, Torbay N, Bracco EF, Hashim SA, Van Itallie TB. Overfeeding with medium-chain triglyceride diet results in diminished deposition of fat. Am J clin Nutr. 1983; 37(1):1-4.
41. Buttiker V, Fanconi S, Burger R. Chylothorax in children: guidelines for diagnosis and

management. Chest. 1999 Sep;116(3):682-7.

42. Panicker KN, Arunachalam N, Kumar NP, Prathibha J, Sabesan S. Efficacy of diethylcarbamazine-medicated salt for microfilaraemia of Brugia malayi. Natl Med J India. 1997 Nov-Dec;10(6):275-6.

43. Pandey AP. Chyluria. In: Morris PJ, Wood WC, editors. Oxford Text of Surgery. second ed. Oxford: Oxford University Press; 2000 p. 3321-3.

44. Mandhani A, Kapoor R, Gupta RK, Rao HS. Can silver nitrate instillation for the treatment of chyluria be fatal? Br J Urol. 1998 Dec;82(6):926-7.

45. Dalela D, Rastogi M, Goel A, Gupta VP, Shankhwar SN. Silver nitrate sclerotherapy for 'clinically significant' chyluria: a prospective evaluation of duration of therapy. Urol Int. 2004;72(4):335-40.

46. Goel S, Mandhani A, Srivastava A, Kapoor R, Gogoi S, Kumar A, et al. Is povidone iodine an alternative to silver nitrate for renal pelvic instillation sclerotherapy in chyluria? BJU Int. 2004 Nov;94(7):1082-5.

47. Dalela D, Gupta VP, Goel A, Singh KM. Omental wrap around the renal pedicle: an adjunctive step to minimize morbidity and recurrence after lymphorenal disconnection for chyluria. BJU Int. 2004 Sep;94(4):673-4.

48. Viswaroop B, Gopalakrishnan G. Open surgery for chyluria. Indian Journal of Urology. 2005;21(1):31-4.

49. Prasad PB, Choudhary DK, Barnwal SN, Jha S, Bharthuar A. Periureteric lympho-venous stripping in cases of chylohaematuria-report of 15 cases. IJS. 1977;39:607-12.

50. Brunkwall J, Simonsen O, Bergqvist D, Jonsson K, Bergentz SE. Chyluria treated with renal autotransplantation: a case report. J Urol. 1990 Apr;143(4):793-6.

51. Chang CY, Lue YB, Lapides J. Surgical treatment for chyluria. J Urol. 1973 Feb;109(2):299-301.

52. Cockett AT, Goodwin WE. Chyluria: attempted surgical treatment by lymphatic-venous anastomosis. J Urol. 1962 Oct;88:566-8.

53. Ji YZ, Zheng JH, Chen JN, Wu ZD. Microsurgery in the treatment of chyluria and scrotal lymphangial fistula. Br J Urol. 1993 Dec;72(6):952-4.

54. Xu YM, Ji RJ, Chen ZD, Qiao Y, Jin NT. Microsurgical treatment of chyluria: a preliminary report. J Urol. 1991 Jun;145(6):1184-5.

55. Jiang J, Zhu F, Jin F, Jiang Q, Wang L. Retroperitoneoscopic renal pedicle lymphatic disconnection for chyluria. Chin Med J (Engl). 2003 Nov;116(11):1746-8.

56. Zhang X, Zhu QG, Ma X, Zheng T, Li HZ, Zhang J, et al. Renal pedicle lymphatic disconnection for chyluria via retroperitoneoscopy and open surgery: report of 53 cases with followup. J Urol. 2005 Nov;174(5):1828-31.

57. Chiu AW, Chen MT, Chang LS. Laparoscopic nephrolysis for chyluria: case report of long-term success. J Endourol. 1995 Aug;9(4):319-22.

58. Badani KK, Hemal AK, Peabody JO, Menon M. Robotic radical prostatectomy: the Vattikuti Urology Institute training experience. World J Urol. 2006 Jun;24(2):148-51.

59. Campieri C, Raimondi C, Dalmastri V, Sestigiani E, Neri L, Giudicissi A, et al. Posttraumatic chyluria due to lymphorenal fistula regressed after somatostatin therapy. Nephron. 1996;72(4):705-7.

60. Giordano M, Crillo D, Baron I, Sorrentino F, Tomasino G, Cicchella T, et al. Treatment of post-traumatic chyluria with subcutaneous octreotide administration. Nephrol Dial Transplant. 1996 Feb;11(2):365-7.

61. Maeda Y, Arima K, Matsuura H, Hayashi N, Yanagawa M, Kawamura J. Percutaneous sclerotherapy for chyluria with leg edema: a case report. Hinyokika Kiyo. 1998 Jan;44(1):25-7.

62. Tuck J, Pearce I, Pantelides M. Chyluria after radical nephrectomy treated with N-butyl-2-cyanoacrylate. J Urol. 2000 Sep;164(3 Pt 1):778-9.

63. Pool MO, van der Hem KG, Stel HV, Luth WJ, Rasker FM, Gans RO. Bilateral excision of perinephric fat and fascia (Gerota's fasciectomy) in the treatment of intractable chyluria. J Urol. 1991 Nov;146(5):1374-6.

64. Yagi S, Goto T, Kawamoto K, Miyawaki I,

Tanaka I, Mori K, et al. Endoscopic treatment of refractory filarial chyluria: a preliminary report. J Urol. 1998 May;159(5):1615-8.

65. Gulati MS, Sharma R, Kapoor A, Berry M. Pelvicalyceal cast formation following silver nitrate treatment for chyluria. Australas Radiol. 1999 Feb;43(1):102-3.
66. Su CM, Lee YC, Wu WJ, Ke HL, Chou YH, Huang CH. Acute necrotizing ureteritis with obstructive uropathy following instillation of silver nitrate in chyluria: a case report. Kaohsiung J Med Sci. 2004 Oct;20(10):512-5.
67. Dash SC, Bhargav Y, Saxena S, Agarwal SK, Tiwari SC, Dinda A. Acute renal failure and renal papillary necrosis following instillation of silver nitrate for treatment of chyluria. Nephrol Dial Transplant. 1996 Sep;11(9):1841-2.
68. Kulkarni AA, Pathak MS, Sirsat RA. Fatal renal and hepatic failure following silver nitrate instillation for treatment of chyluria. Nephrol Dial Transplant. 2005 Jun;20(6):1276-7.
69. Moufid K, Mejean A, Balian C, Bazin JP, Dufour B, Eiss D, et al. Laparoscopic kidney release for refractory chyluria. Prog Urol. 2005 Feb;15(1):72-4; discussion 4.
70. Yu HH, Ngan H, Leong CH. Chyluria--a 10 year follow-up. Br J Urol. 1978 Apr;50(2):126-33.
71. Ohyama C, Saita H, Miyasato N. Spontaneous remission of chyluria. J Urol. 1979 Mar;121(3):316-7.
72. Okamoto K, Ohi Y. Recent distribution and treatment of filarial chyluria in Japan. J Urol. 1983 Jan;129(1):64-7.
73. Tan LB, Chiang CP, Huang CH, Chou YH, Wang CJ. Experiences in the treatment of chyluria in Taiwan. J Urol. 1990 Sep;144(3):710-3.
74. Sabnis RB, Punekar SV, Desai RM, Bradoo AM, Bapat SD. Instillation of silver nitrate in the treatment of chyluria. Br J Urol. 1992 Dec;70(6):660-2.
75. Shanmugam TV, Prakash JV, Sivashankar G. Povidone iodine used as a sclerosing agent in the treatment of chyluria. Br J Urol. 1998 Oct;82(4):587.
76. Punekar SV, Kelkar AR, Prem AR, Deshmukh HL, Gavande PM. Surgical disconnection of lymphorenal communication for chyluria: a 15-year experience. Br J Urol. 1997 Dec;80(6):858-63.